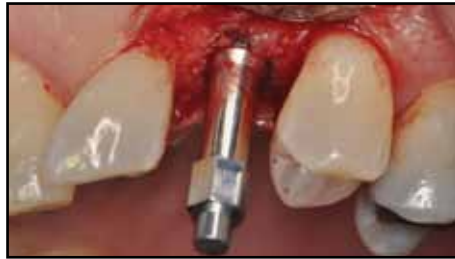

Case Reports Describing The “Bump”: A New Phenomenon in Implant Healing

**Paul S. Rosen, DMD, MS¹ • Neil Meredith BDS, PhD²
Mark A. Reynolds, DDS, PhD³**

Abstract



This article presents 28 cases demonstrating a phenomenon that will be termed the “Bump”. Historically, implants have seen an early decrease in their stability as healing progressed from primary mechanical stability to biologic bone remodeling and formation better known as osseointegration. The lag between the predominance of biologic over mechanical stability has been termed the dip. This can be quantitatively measured by resonance frequency analysis (RFA) where the implant stability quotient (ISQ) values decrease with time

from those seen at placement until osseointegration causes an increase back to and quite possibly greater than those initially measured. The patients presented in these case reports were treated with enhanced surface implants exhibiting electro-wetting and demonstrated ISQ values during early healing periods of 2 and 4 weeks that were significantly higher than those measured at insertion. The possibility that this may relate to accelerated wound healing should be considered, expanding the option for loading such implants at an earlier time frame.

KEY WORDS: Dental implants, bone, remodeling, osseointegration, implant stability quotient, electrowetting

1. Private practice limited to Periodontics and Dental Implants, Yardley, Pennsylvania, USA. Clinical Associate Professor of Periodontics, Baltimore College of Dental Surgery, University of Maryland Dental School, Baltimore, Maryland, USA

2 CEO of Neoss Ltd., Professor of Restorative Dentistry and Biomaterials at Leeds Dental Institute, University of Leeds, United Kingdom

3 Chairman of the Department of Periodontics, Baltimore College of Dental Surgery, University of Maryland Dental School, Baltimore, Maryland, USA

INTRODUCTION

Implant osseointegration has revolutionized the way that we treat our patients today. Initially, implants provided a means for the dentally compromised patient to regain mastication and phonetics.^{1,2} Today however, patient expectations have also come to include receiving an implant-supported prostheses that is more esthetic while being delivered on a more timely basis. Dental implant surface roughening has reduced the time for implant healing while enabling greater success rates.³⁻⁵

The process for achieving successful osseointegration progresses from initial primary/mechanical stability of the dental implant where non-integrated bone and blood clot contact the implant's surface upon its placement to secondary or biologic stability where both are replaced by contact or distant osteogenesis.⁶ Historically, this transition in implant stabilization from mechanical to biological has demonstrated a phenomenon known as the "dip",⁷ coinciding with the first 2-8 weeks of healing, depending upon the implant's surface and the nature of the bone-implant interface.⁸ Changes in implant stability have been quantitatively measured historically through the use of resonance frequency analysis (RFA)^{9,10}. In the case of a dip, the implant stability quotient (ISQ) would initially diminish owing to a decrease in implant micro stiffness, only to recover to the initial reading at implant placement or quite possibly to a value that might be higher based on an increase in bone to implant contact. Until there is evidence of an increase or maintenance in stability in ISQ from the dip's nadir, patients are typically expected to wait for restoration of their implants. While roughening the surface has increased the speed of

osseointegration, it has not obviated the dip.

A more recent approach to increasing the speed of osseointegration has been to reduce surface contamination and to increase bio-adhesion/surface retention of the clot. This may be achieved by a combination of titanium particle blasting and acid etching of the surface followed by submitting it to electrochemical wetting to decrease surface tension enhance clot adhesion and bone deposition. By eliminating surface tension and overcoming bridging effects, electro-wetting an implant allows blood and tissue fluids containing growth factors and other essential proteins to be drawn into intimate contact with its roughened surface. In vivo studies have demonstrated that by placing ions on the ProActive[®] implant's surface, an electrical charge is generated when contacting a patient's blood, leading to greater clot stability and earlier bone deposition.

It is the purpose of this paper to present clinical cases where electro-wetted implants have been placed and RFA values have demonstrated no dip, but on the contrary, rises in values at intervals of two and four weeks post insertion. These values suggest that the dip may be eliminated and replaced by a "bump" in osseous healing which may allow for consideration to earlier restoration of these particular implants.

CASE TREATMENTS

Patients were referred to a practice limited to periodontics and dental implants for the replacement of missing or failing teeth. All received informed consent prior to the planned care. Immediately prior to the surgical procedure, patients rinsed and brushed with a 0.12% chlorhexidine mouthwash. Anesthesia was obtained using local infiltration with articaine 4% with 1:100,000 epinephrine

Table 1: Patient Information

| Implant ID | Patient Gender | Patient Age | Insertion Torque (Ncm) | ISQ 1 Measurement at Placement | ISQ 2 Measurement at Placement | ISQ 1 Measurement at 2 weeks | ISQ 2 Measurement at 2 weeks | ISQ 1 Measurement at 4 weeks | ISQ 2 Measurement at 4 weeks |
|------------|----------------|-------------|------------------------|--------------------------------|--------------------------------|------------------------------|------------------------------|------------------------------|------------------------------|
| 1 | F | 68 | 32 | 80 | 80 | 84 | 85 | NR | NR |
| 2 | F | 59 | 32 | 79 | 82 | 83 | 85 | 85 | 85 |
| 3 | F | 70 | 32 | 70 | 78 | 78 | 78 | 76 | 76 |
| 4 | M | 55 | 32 | 71 | 75 | 77 | 80 | 79 | 79 |
| 5 | M | 69 | 32 | 72 | 75 | 72 | 79 | 79 | 80 |
| 6 | M | 63 | 32 | 71 | 71 | 76 | 72 | 75 | 77 |
| 7 | M | 63 | 32 | 58 | 77 | 75 | 70 | 77 | 77 |
| 8 | M | 52 | 32 | 75 | 78 | 85 | 80 | 85 | 84 |
| 9 | M | 65 | 32 | 70 | 80 | 78 | 80 | 79 | 79 |
| 10 | F | 62 | 32 | 65 | 76 | 76 | 76 | 77 | 77 |
| 11 | F | 63 | 32 | 74 | 79 | 79 | 80 | 74 | 76 |
| 12 | M | 55 | 32 | 66 | 75 | 71 | 71 | 70 | 70 |
| 13 | F | 40 | 32 | 65 | 66 | 74 | 76 | 80 | 80 |
| 14 | F | 69 | 32 | 77 | 84 | 85 | 84 | 85 | 84 |
| 15 | M | 61 | 32 | 60 | 66 | 71 | 71 | 64 | 65 |
| 16 | M | 53 | 32 | 60 | 76 | 73 | 76 | 72 | 74 |
| 17 | F | 66 | 32 | 78 | 78 | 77 | 82 | 81 | 82 |
| 18 | M | 55 | 32 | 65 | 80 | 79 | 80 | NR | NR |
| 19 | M | 76 | 32 | 72 | 77 | 77 | 77 | 75 | 75 |
| 20 | M | 76 | 32 | 75 | 79 | 80 | 80 | 79 | 80 |
| 21 | F | 59 | 32 | 76 | 81 | 81 | 81 | 81 | 81 |
| 22 | M | 62 | 32 | 76 | 83 | 84 | 84 | 86 | 86 |
| 23 | M | 65 | 32 | 73 | 73 | 78 | 78 | 77 | 77 |
| 24 | M | 68 | 32 | 74 | 74 | 81 | 80 | 80 | 77 |
| 25 | F | 50 | 32 | 75 | 75 | 75 | 80 | 73 | 77 |
| 26 | M | 48 | 32 | 75 | 75 | 75 | 79 | 73 | 77 |
| 27 | F | 51 | 32 | 67 | 67 | 71 | 72 | 74 | 73 |
| 28 | F | 51 | 32 | 67 | 72 | 72 | 72 | 64 | 72 |

or articaine 4% with 1:200,000 epinephrine (Septocaine[®], Septodont, Inc. New Castle, Delaware 19720). Full thickness flaps were elevated and the surgical area was fully visualized. Implant placement followed the manufacturer's protocol.

Sites included both those that had completely healed following tooth extraction or where immediate removal of a tooth had been performed. Following the preparation of the osteotomy, an implant whose surface had been micro rough-

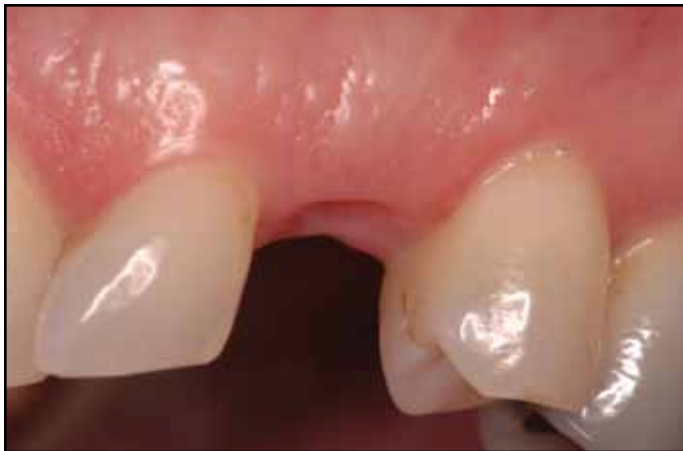

Figure 1a: Pretreatment view of the maxillary left canine site in this healthy 53 year old healthy male. The tooth had been extracted 3 months prior to the implant being placed.

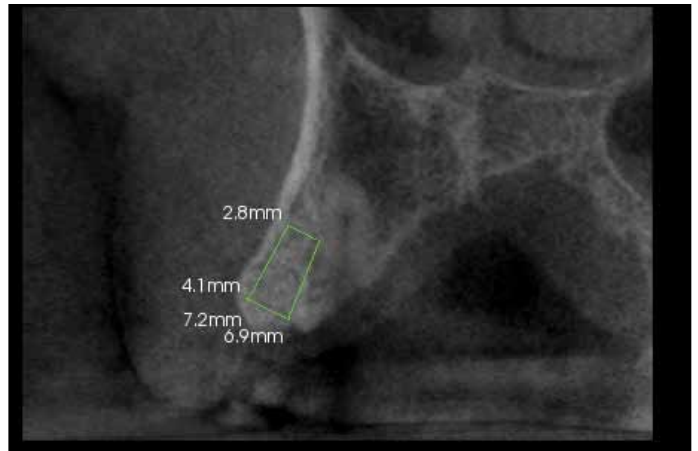


Figure 1b: Conebeam radiograph reveals that the permanent canine will limit the length of implant placement. A mocked up rendition of a 4X7 mm implant is placed to determine its appropriateness.

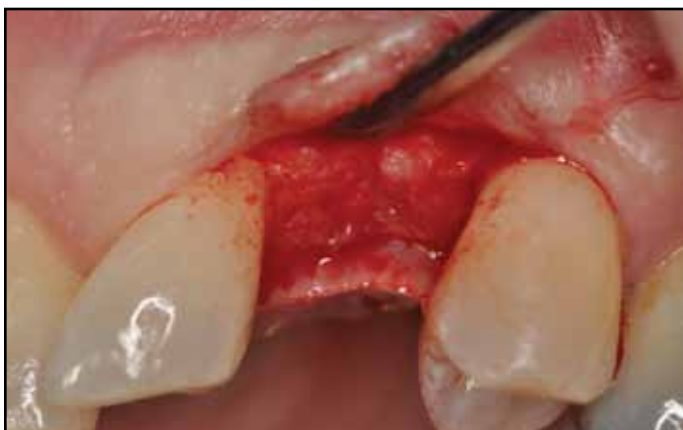

Figure 1c: Flap reflection of the site suggests good bone width for implant placement.

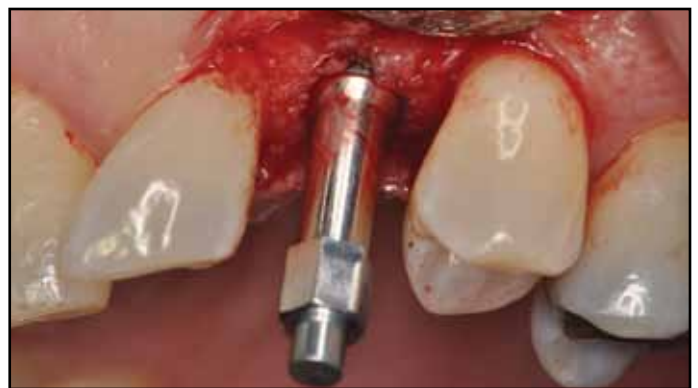

Figure 1d: A smartpeg has been placed on the 4x7 mm implant at initial insertion. The insertion was 32 Ncm with ISQ readings of 60 in the buccal-palatal direction and 76 mesio-distally.

ened by both blasting followed by acid etching and electro-wetting (Proactive[®], Neoss, Harrogate, England) was fully seated and resonance frequency analysis (Osstell ISQ Instrument, Osstell AB, Gothenburg, Sweden) was performed with values recorded in both the buccal-lingual and mesial-distal directions. Any necessary bone augmentation was performed using a mineral-

ized allograft (LifeNet Health, Virginia Beach, Virginia) hydrated with recombinant platelet derived growth factor-BB (rh-PDGF-BB) (Osteohealth, Shirley, New York). Implant abutments made from polyetherether-ketone (PEEK), which came packaged with the implants, were placed and kept transgingival enabling RFA's to be obtained at subsequent visits. Suturing of the flaps was

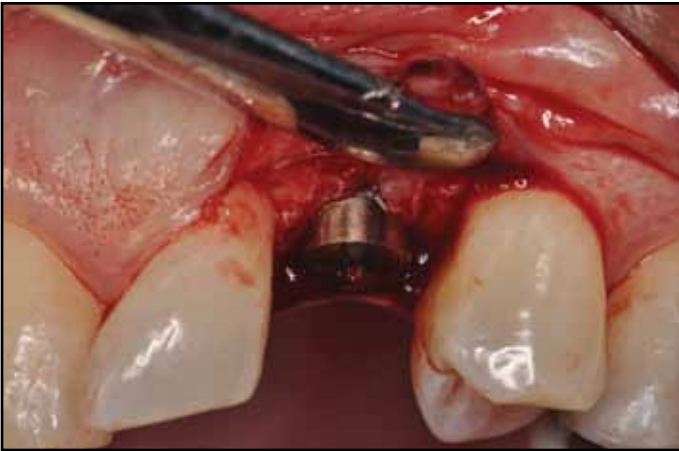

Figure 1e: A 2mm titanium abutment will allow for transgingival suturing of the implant.

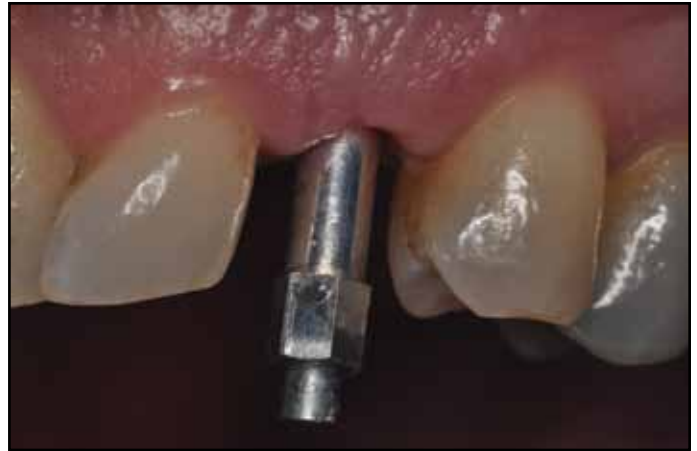

Figure 1f: Two week healing with the smartpeg in place. The ISQ's are now 73 in the buccal-palatal direction which has shown a substantial bump and 76 mesio-distally.

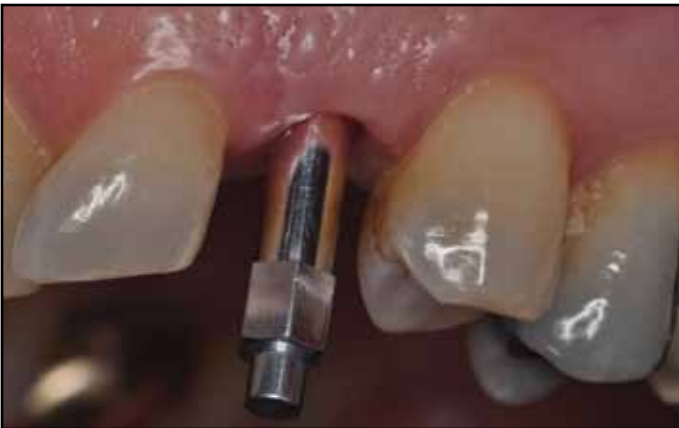

Figure 1g: Four week healing shows good soft tissue response. A bump from baseline is still present with the ISQ's now reading 72 buccal-palatally and 74 mesio-distally.

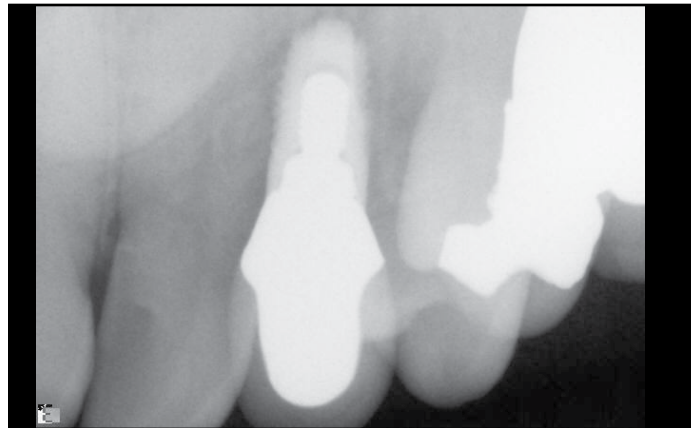


Figure 1h: Final radiograph suggests good crown margins and the implant just avoiding the impacted cuspid.

achieved using 6-0 expanded polytetrafluoroethylene (W.L. Gore & Associates, Flagstaff, Arizona).

Postoperative management included the use of amoxicillin 875 mg twice daily for 7 days along with the use of 0.12% chlorhexidine gluconate mouthrinse topically applied twice daily for at least the first 28 days. If the patient was allergic to amoxicillin, then either clindamycin

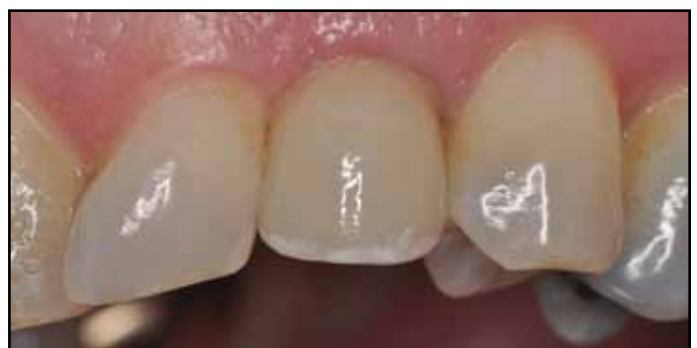

Figure 1i: Clinical view of the final crown at 6 months following implant placement.

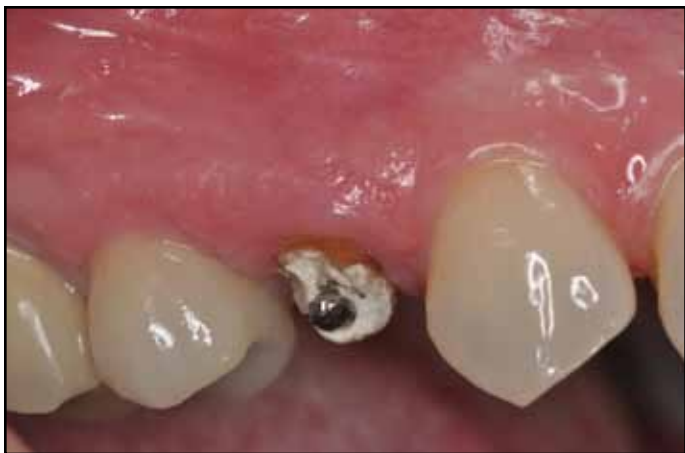

Figure 2a: Pretreatment clinical view of the maxillary right first premolar in this 62 year old whose medical history includes osteopenia. No medication is taken for this other than vitamin D and calcium.

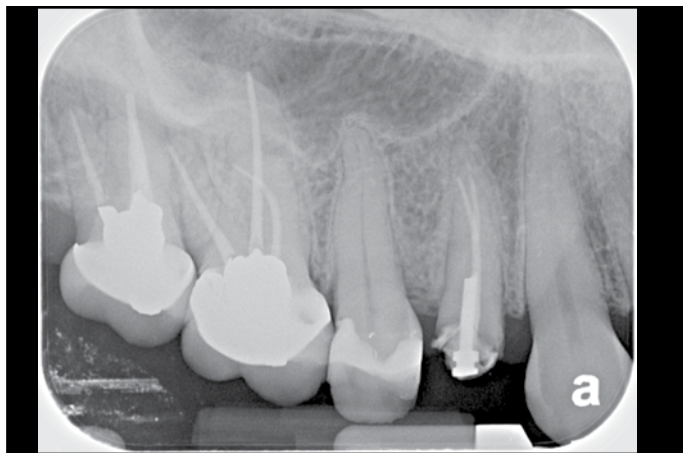


Figure 2b: The first premolar has vertical root fracture in addition to recent crown loss that make it untreatable.

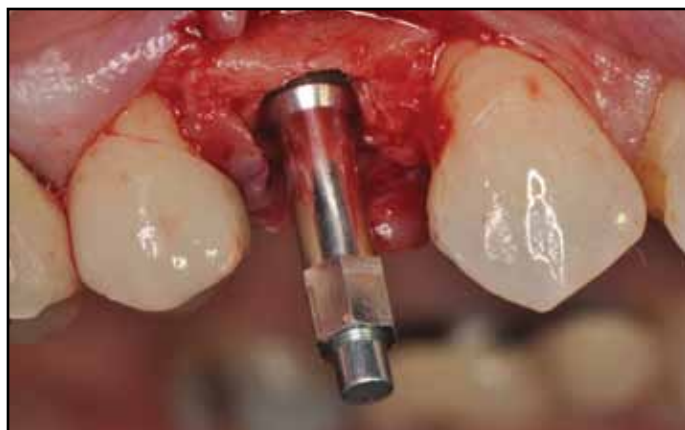

Figure 2c: Extraction is performed and immediate placement of the implant is accomplished. The final insertion torque is 32Ncm. There is a 1 mm labial gap that will be subsequently grafted with FDBA combined with PDGF-BB. The smartpeg has been positioned and the ISQ values are 65 for buccal-palatal and 76 for the mesial-distal direction.

150 mg taken four times daily for seven days or azithromycin 500 mg taken on the first day followed by 250 mg per day for the next four days was substituted. For pain management, patients used ibuprofen 600-800 mg up to four

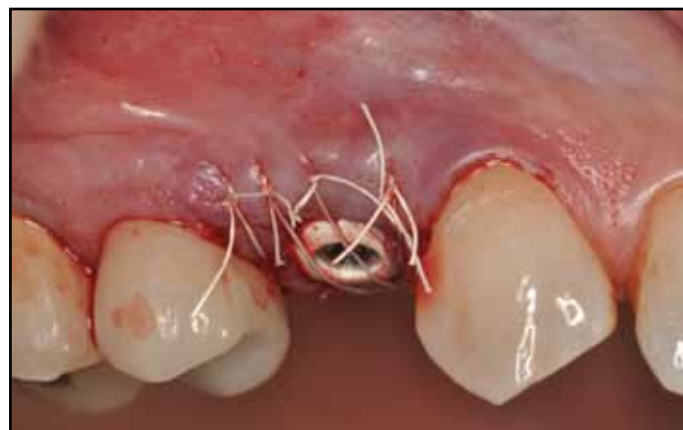

Figure 2d: Suturing of the flap with 7-0 ePTFE was performed to further assist in graft containment.

times per day or acetaminophen with codeine # 3 taken every four-six hours if non-steroidal anti-inflammatory agents could not be taken.

Suture removal took place at 14 ± 3 days post-implant insertion. At the time of the visit, RFA was repeated and recorded in the same directions as at the time of implant placement. If a removable prosthesis was worn it was checked, adjusted, relined or replaced if neces-

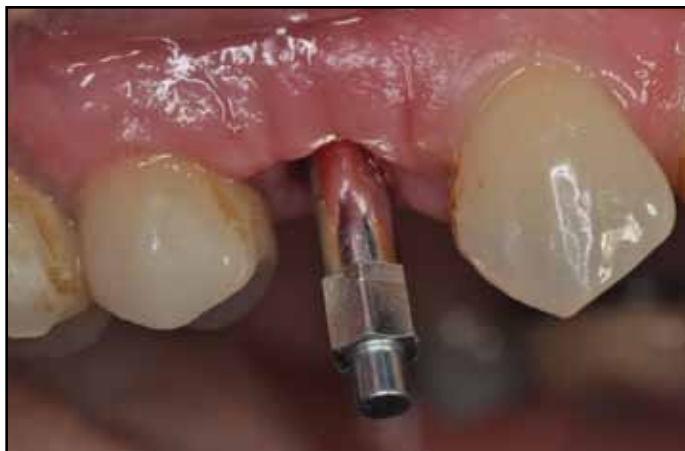

Figure 2e: RFA values taken at the time of 2 weeks following implant placement. The ISQ is 76 for both buccal-palatal and mesial-distal directions.

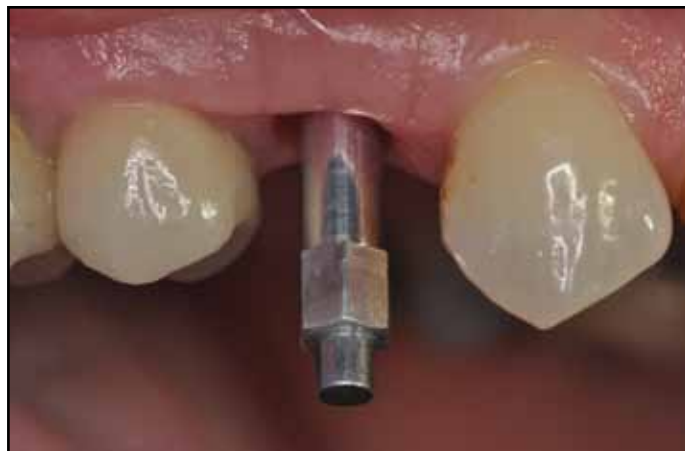

Figure 2f: RFA values at 4 weeks are 77 for both the buccal-palatal and mesial-distal directions. Soft tissue healing has progressed favorably as well.

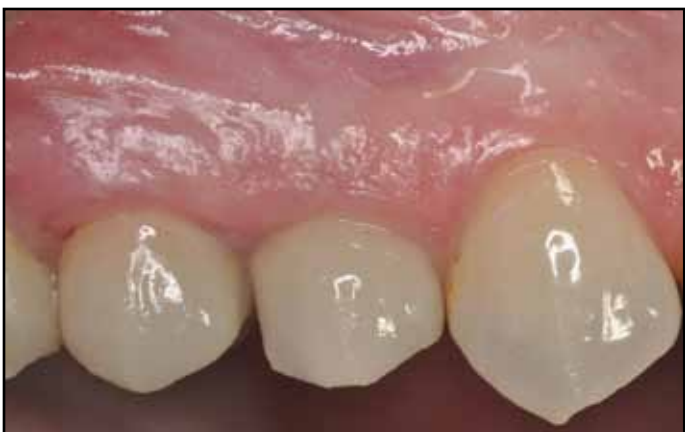

Figure 2g: Clinical view of the final crown placement at 8 months post surgery. The crown is screw retained with the soft tissue response being quite favorable.

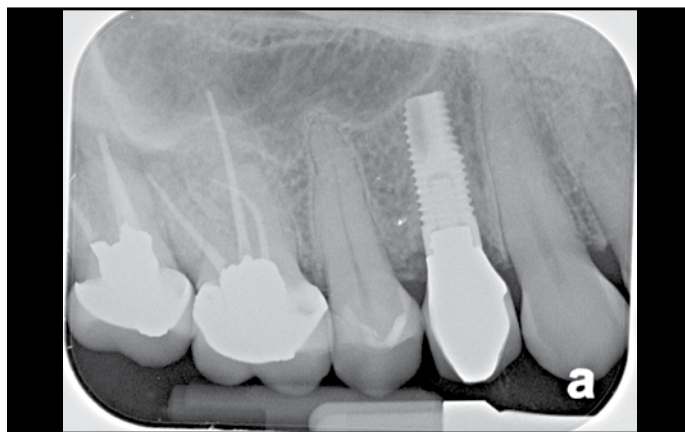


Figure 2h: Periapical radiograph of the seated final crown suggests good bone stability.

sary and lightly adherent plaque was removed by topical application of a 0.12% chlorhexidine mouth rinse. The subsequent postoperative visit was at 28 ± 3 days at which time RFA was repeated and recorded along with appliance evaluation and plaque removal. If RFA values remained stable or improved, impressions were taken for the final prosthesis was scheduled with the restorative dentist/prosthodontist.

RESULTS

The patients reported on here were a part of a larger group that was consecutively treated and all followed this protocol and will be detailed in a subsequent paper. All had bone that could be categorized as type I-III, achieved an insertion torque of 25Ncm or better (average of 31.8) and had an ISQ reading of 58 or greater. The ISQ values were all obtained from the same Osstell

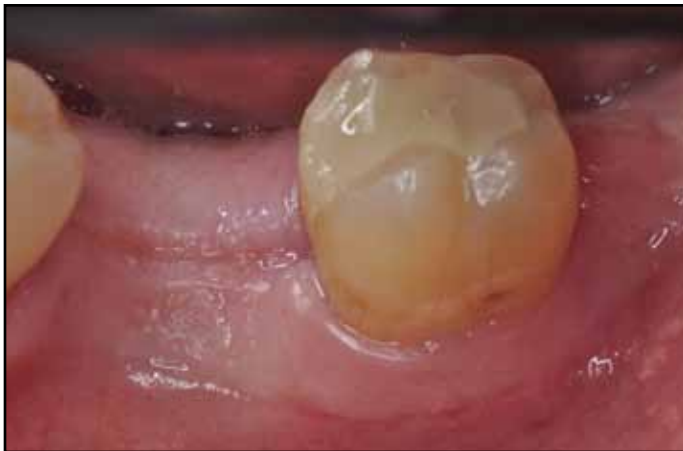

Figure 3a: Preoperative clinical view of the mandibular left first molar site in a 53 year old male who was a former smoker until one year prior.

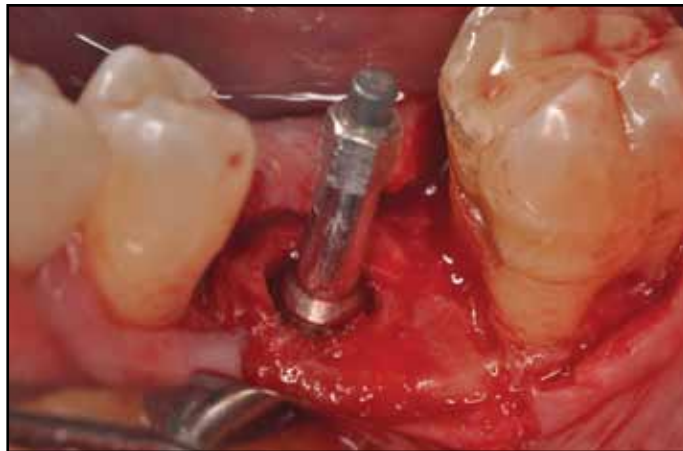


Figure 3b: Implant was placed into Type II bone to 32Ncm. ISQ values are 75 in the buccal-lingual direction and 78 in the mesio-distal direction.

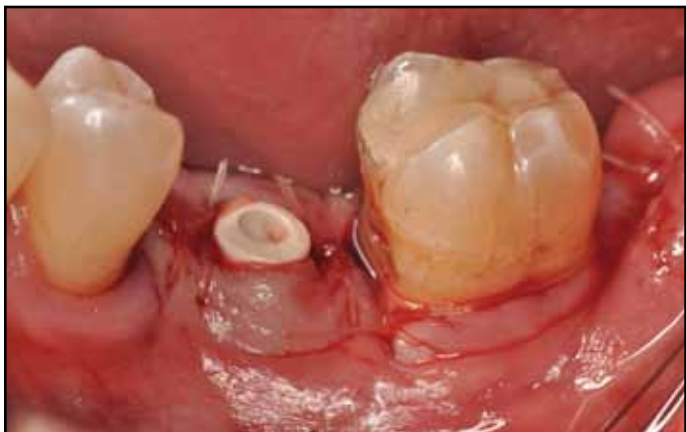

Figure 3c: Implant received a 4 mm PEEK healing abutment which was sutured transgingivally with 4-0 gut.

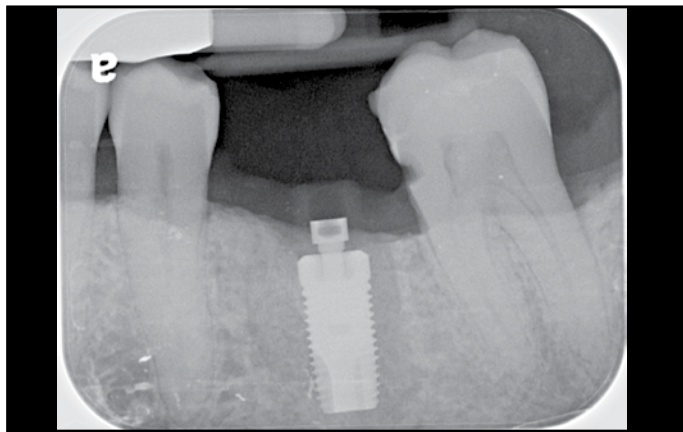


Figure 3d: Radiograph of the placed implant.

device. Table 1 summarizes the initial and subsequent ISQ values along with insertion torques obtained for these implants. The accuracy of the Osstell is ± 2 ISQ units¹¹ and so implants exhibiting increases in ISQ of 3 or greater in at least one direction with the other, remaining at least stable, were considered significant and included. Figures 1a-i to 3a-i present several representative cases amongst the group.

DISCUSSION

These case reports appear to indicate that an implant with a microroughened electro-wetted surface to achieve rapid clinical healing. While no patients received restorations immediately, this did serve as the basis to further explore this possibility.

Efforts have traditionally focused on increasing the speed of osseointegration by modifying the macro and/or micro geometry of the

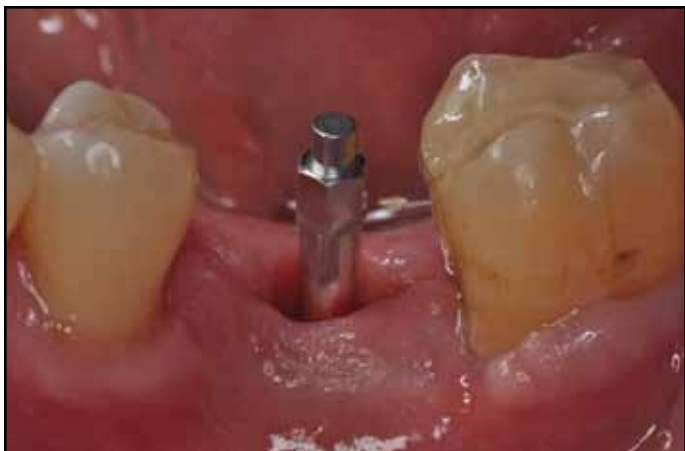

Figure 3e: Smartpeg in place at 2 week post-op. ISQ values are 85 in the buccal-lingual and 80 in the mesial-distal directions.

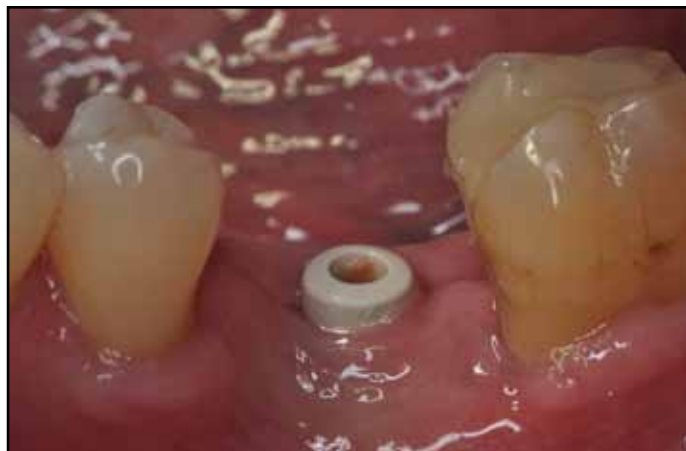

Figure 3f: Post-operative view of tissue healing at 4 weeks.

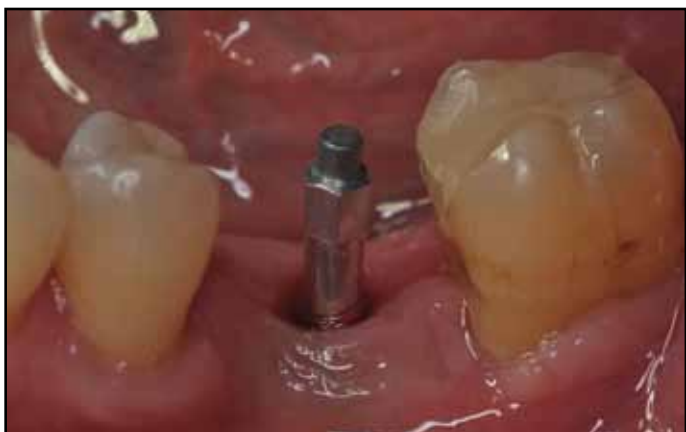

Figure 3g: Smartpeg placed at 4 weeks. ISQ's are 85 in the buccal-lingual and 84 in the mesial-distal directions.

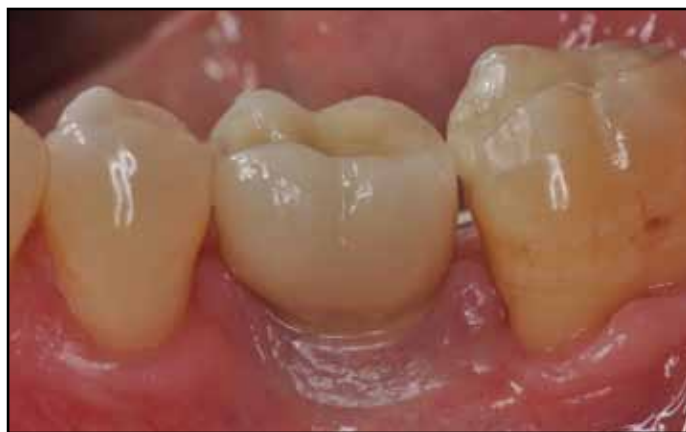

Figure 3h: Clinical view of the final crown placement at 4 months post surgery.

dental implant surface. While roughening an implant surface has enhanced osseointegration^{3,7}, increasing the roughness of a surface may also create pits causing air to be trapped under a liquid layer preventing wetting. Furthermore, the aspect ratio (height or depth of troughs or porosities in relation to their width or circumference) of the topography is critical as this may cause bridge formation resulting in a failure of a fluid to penetrate such features.¹²

More recently, efforts have shifted toward surface modifications in surface chemistry that would lead to greater reactivity. Manufacturing an implant in a nitrogen rich environment with subsequent storage in a solution of physiologic saline is one method that looks to enhance the chemical purity and retained surface energy of an implant's surface to give it enhanced hydrophilic properties¹³. Baier¹⁴ has discussed that there is a correlation between biocompatibility,

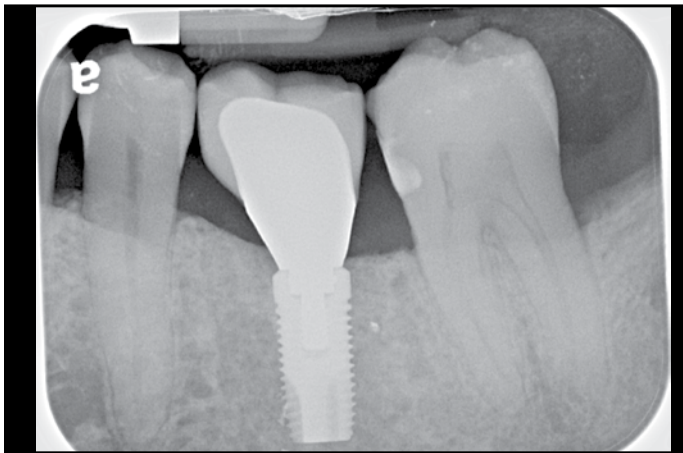


Figure 3i: Radiograph of the final crown suggests good maintenance of bone levels at 4 months post-placement.

bio-adhesion and surface tension or contact angle on a substrate or implant surface. By improving adherence of the blood clot to the implant's surface, the process of healing may proceed more quickly, allowing for an implant to be placed into earlier function. If the dental implant's surface could become more "reactive" by increasing surface energy in the form of hydrophilicity and surface charge, it might be possible to accelerate the speed of bone-to-implant contact. In vivo studies have suggested that the shift from primary to secondary stability takes place over approximately eight weeks for rough surface implants while chemical surface modifications have reduced this further.¹⁵

Electro-wetting is a possible method that attempts to enhance the reactivity of a dental implant's surface. The electro-wetting process on a titanium surface enables increased hydrophilicity, maximizing the penetration of blood and its components, fibrin, complement and growth factors into the implant surface. This is achieved by an ionic surface treatment that creates an electrical charge on the implant surface dur-

ing placement and breaks down the interfacial surface tension between the blood and implant surface (Electro-wetting on Dielectric [EWOD]). The contact angle of such a treated implant is 0° . Animal studies have corroborated this phenomenon with animal histology demonstrating bone deposition outpacing resorption as early as 10 days.¹⁶ Removal torque was consistent with the histology since values were higher versus other implant surfaces as early as 10 days lasting up to 6 weeks.¹⁶ While animal data serves as a good first step, this needs to be corroborated in humans.

These cases were all treated in a clinician's private practice and serve as initial clinical evidence to corroborate the in-vivo animal data. RFA has been used in practice as it is a noninvasive, safe method of obtaining objective information on healing to make the clinical decision of when to provisionalize or load the implant. While these patients are only 28 in number, they are a significant sample to say with confidence that this is simply not a chance finding but rather a consequence of enhanced conductive properties to this implant surface. The value of 3 ISQ was used to determine a bump in healing as the accuracy of the Ostell machine is ± 2 units. What is interesting is that the vast majority of the sites retained this bump phenomenon at 4 weeks and that none demonstrated a dip from the baseline throughout the 4 week time period. Furthermore, there needs to be controlled corroboration of whether the high level of surface conductivity coupled with a high value of early stability make these implants better candidates for routine immediate or very early provisionalization.

Several trends are worth noting in these

case reports. The majority of the bumps occurred in a buccal-lingual/palatal direction rather than mesiodistally and that this trend remained true for the majority of the implants at 4 weeks as well as at 2. This may relate to the higher ISQ values at insertion at mesial and distal sites and there being a lower likelihood for an increase to have occurred. In those implants that were immediately placed, there appeared to be a trend for fixtures with high ISQ levels to decrease and low ISQ levels to increase over time (Table 1).

In conclusion, this preliminary observation from a clinical private practice is an exciting finding. To our knowledge, no one else has reported on this nor has there been any in depth evaluation of its implication on clinical practice. It certainly suggests, at the very least, that this electro-wetted surface implant, when placed in a healthy patient, heals quite rapidly. Further study in larger controlled trials appear warranted to determine what is or are the exact reasons for this faster healing, if this could possibly translate to more frequently provisionalizing/loading this implant either immediately or very early, i.e. at 2 weeks, with the risk of failure being less likely usher in an era of implant care that comes closer to meeting the desire of our patients to achieve final outcomes sooner. ●

Correspondence:

Dr. Paul S. Rosen
907 Floral Vale Blvd
Yardley, PA 19067-5515
(215) 579-0907

Disclosures

Dr. Reynolds reports no conflicts associated with this article.
Dr. Rosen has lectured for Neoss and Osstell.
Dr. Meredith is one of the founders and is currently employed by Neoss.

Acknowledgements

The authors wish to thank Nyree Divitini for assistance in the preparation of this manuscript.

References

- Zarb GA, Schmitt A. The longitudinal clinical effectiveness of osseointegrated dental implants: the Toronto Study. Part II: The prosthetic results. *J Prosthet Dent.* Jul 1990;64(1):53-61.
- Zarb GA, Schmitt A. The longitudinal clinical effectiveness of osseointegrated dental implants: the Toronto study. Part I: Surgical results. *J Prosthet Dent.* Apr 1990;63(4):451-457.
- Cochran DL. A comparison of endosseous dental implant surfaces. *J Periodontol.* Dec 1999;70(12):1523-1539.
- Shalabi MM, Gortemaker A, Van't Hof MA, Jansen JA, Creugers NH. Implant surface roughness and bone healing: a systematic review. *J Dent Res.* Jun 2006;85(6):496-500.
- Wennerberg A, Albrektsson T. Effects of titanium surface topography on bone integration: a systematic review. *Clin Oral Implants Res.* Sep 2009;20 Suppl 4:172-184.
- Schouten C, Meijer GJ, van den Beucken JJ, Spauwen PH, Jansen JA. The quantitative assessment of peri-implant bone responses using histomorphometry and micro-computed tomography. *Biomaterials.* Sep 2009;30(27):4539-4549.
- Raghavendra S, Wood MC, Taylor TD. Early wound healing around endosseous implants: a review of the literature. *Int J Oral Maxillofac Implants.* May-Jun 2005;20(3):425-431.
- Friberg B, Sennerby L, Linden B, Grondahl K, Lekholm U. Stability measurements of one-stage Branemark implants during healing in mandibles. A clinical resonance frequency analysis study. *Int J Oral Maxillofac Surg.* Aug 1999;28(4):266-272.
- Meredith N, Alleyne D, Cawley P. Quantitative determination of the stability of the implant-tissue interface using resonance frequency analysis. *Clin Oral Implants Res.* Sep 1996;7(3):261-267.
- Meredith N, Book K, Friberg B, Jemt T, Sennerby L. Resonance frequency measurements of implant stability in vivo. A cross-sectional and longitudinal study of resonance frequency measurements on implants in the edentulous and partially dentate maxilla. *Clin Oral Implants Res.* Jun 1997;8(3):226-233.
- Nedir R, Bischof M, Szmukler-Moncler S, Bernard JP, Samson J. Predicting osseointegration by means of implant primary stability. *Clin Oral Implants Res.* Oct 2004;15(5):520-528.
- Le Guehennec L, Soueidan A, Layrolle P, Amouriq Y. Surface treatments of titanium dental implants for rapid osseointegration. *Dent Mater.* Jul 2007;23(7):844-854.
- Rupp F, Scheideler L, Olshanska N, de Wild M, Wieland M, Geis-Gerstorfer J. Enhancing surface free energy and hydrophilicity through chemical modification of microstructured titanium implant surfaces. *J Biomed Mater Res A.* Feb 2006;76(2):323-334.
- Baier RE. The role of surface energy in thrombogenesis. *Bull N Y Acad Med.* Feb 1972;48(2):257-272.
- Oates TW, Valderrama P, Bischof M, et al. Enhanced implant stability with a chemically modified SLA surface: a randomized pilot study. *Int J Oral Maxillofac Implants.* Sep-Oct 2007;22(5):755-760.
- Gottlow JS, Sennerby L. Influence of surface and implant design on stability of five commercial titanium implants: A biomechanical study in the rabbit. *Academy of Osseointegration.* Orlando, 2010.